

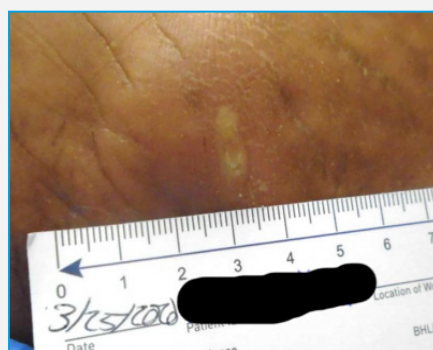Speed of Healing following Debridement of a Charcot Foot wound using the Medaxis debritom+ micro water jet technology

Florence Summers DPM, Audra R Siegel DPM, Christopher K Bromley DPM, Premier Medical Group, Poughkeepsie NY

Background

Patient is a 42-year-old female with a history of poorly controlled diabetes and a history of Charcot to the right foot who currently ambulates in a Crow walker. Patient also relates a history of osteomyelitis to the right great toe (2016). A new micro water jet technology called debritom+ by Medaxis was used to treat a wound that was failing to respond to standard of care treatment.

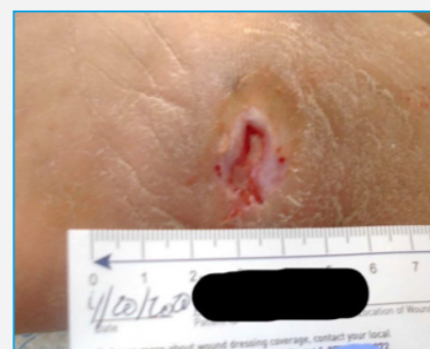Wound Day 1



30 Days before use of Medaxis debritom+

Patient presents as an emergency with complaints of a blister on the bottom of her right foot that was noticed the night before. Blister was located on the plantar aspect of the right foot, with edema and erythema present. Blister was debrided utilizing a #20 blade. Wound measurements were 1 x 0.3 x 0.2 cm. Culture was taken. Triple antibiotic ointment and a dry sterile dressing was applied and patient was placed on Keflex. Weekly sharp debridement with localized wound care led to moderate improvement.

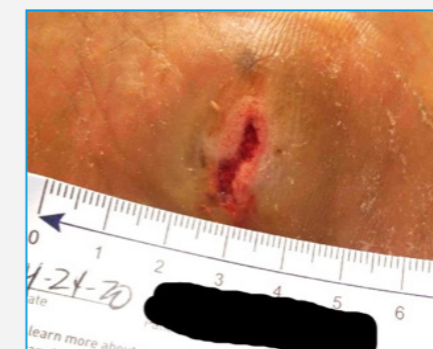Wound Day 26



4 Days before use of Medaxis debritom+

Patient again presented as an emergency. Significant drainage is noted on the dressings and erythema is again noted. Ulceration increased dramatically to 1.5 x 1.0 x 0.2 cm, and again sharp debridement was performed and a culture taken. Patient was again placed on Keflex and a dressing with Acticoat 7 was applied.

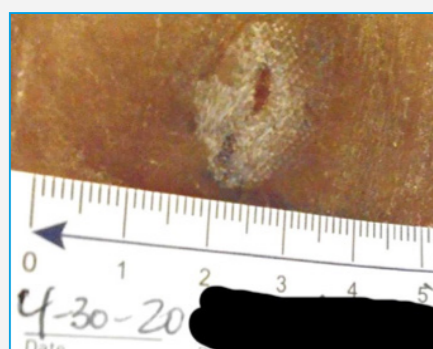
Wound Day 30



Treatment with Medaxis debritom+

Patient returned to clinic. Wound showed no signs of infection with some improvement in ulceration, however continued drainage was noted. Ulceration measured 1.5 x 0.3 x 0.2 cm. To expedite healing, reaming was performed utilizing the Medaxis debritom+. A dressing including Acticoat 7 was applied.

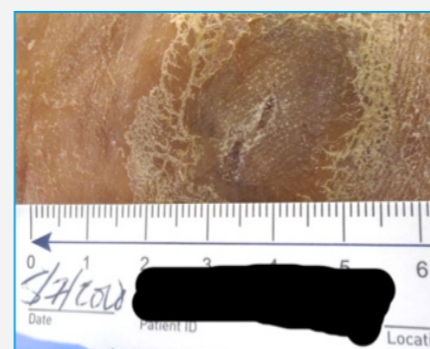
Wound Day 36



Medaxis debritom+ Treatment Day 6

Patient returns to clinic. No signs of infection and no drainage is noted. Ulceration is markedly improved, measuring 0.3 x 0.1 x 0.1 cm. No further debridement was required. Acticoat 7 dressing was applied.

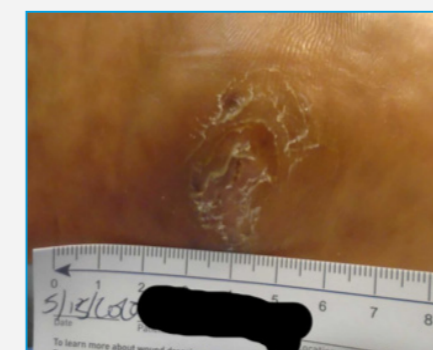Wound Day 43



Medaxis debritom+ Treatment Day 13

Patient returns to clinic. Ulceration is closed.

Wound Day 51



Medaxis debritom+ Treatment Day 21

Ulceration remains closed

Conclusion

After multiple treatments with sharp debridement over the course of 4.5 weeks, the wound failed to heal. Subsequently a single debridement performed with the Medaxis debritom+ micro water jet technology device, resulted in closure of the wound in under 1 week. This device proved to be simple to use, and efficacious in facilitating wound healing.

debritom+

