

Amputation is not the only option: The use of a novel micro water jet technology for limb salvage in lower extremity gangrene

Anna Sanchez DPM¹, Susan Brantley-Smith RN WCC², Joseph Coles EMT^{1,3}

¹San Antonio New Step Foot Clinic, San Antonio, TX. ²Medaxis LLC, Plano, Tx. ³Bio-X-Cell-Research, San Antonio, TX

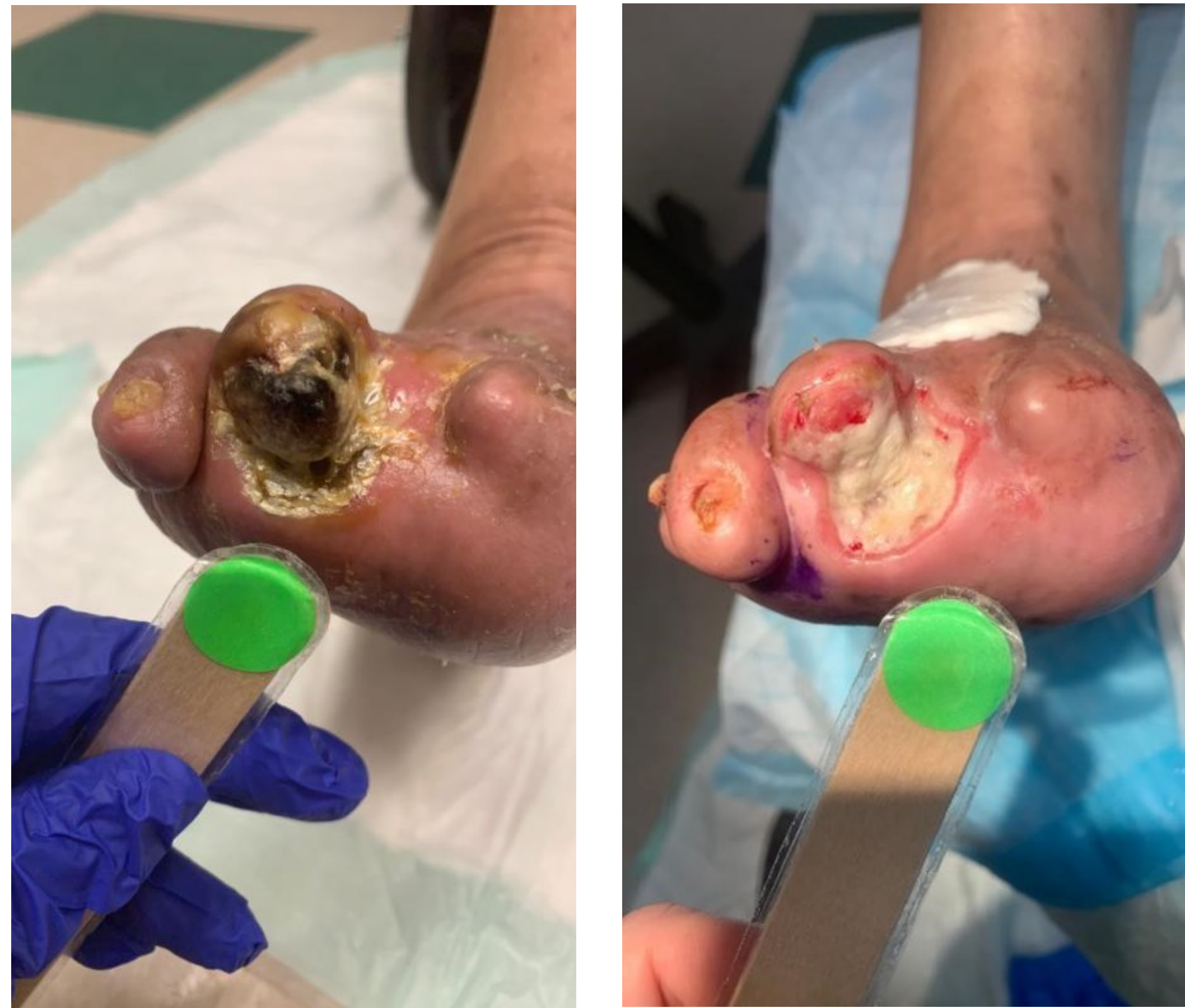Introduction

In the U.S. 185,000 LEA (lower extremity amputations) are performed each year, of which 82% are due to poor vascular health and preceded by an ulcer. Debridement removes necrotic/devitalized tissue, but for gangrene there are limited to non-existent techniques available, leaving amputation as the default treatment. The patient's quality of life is severely impacted and the medical costs resulting from amputation are significant, with the total lifetime cost per patient estimated at \$500,000.

Methods

The micro water jet device debritom⁺ offers a precision in debridement not previously available to wound care patients, in that it removes devitalized tissue while leaving healthy tissue intact. As the only device offering this precision, we assessed debritom⁺ in the office setting in patients with lower extremity gangrene scheduled for amputation. Presented here are 3 of many patients that benefited from gangrene resolution in our practice.

Patient 1



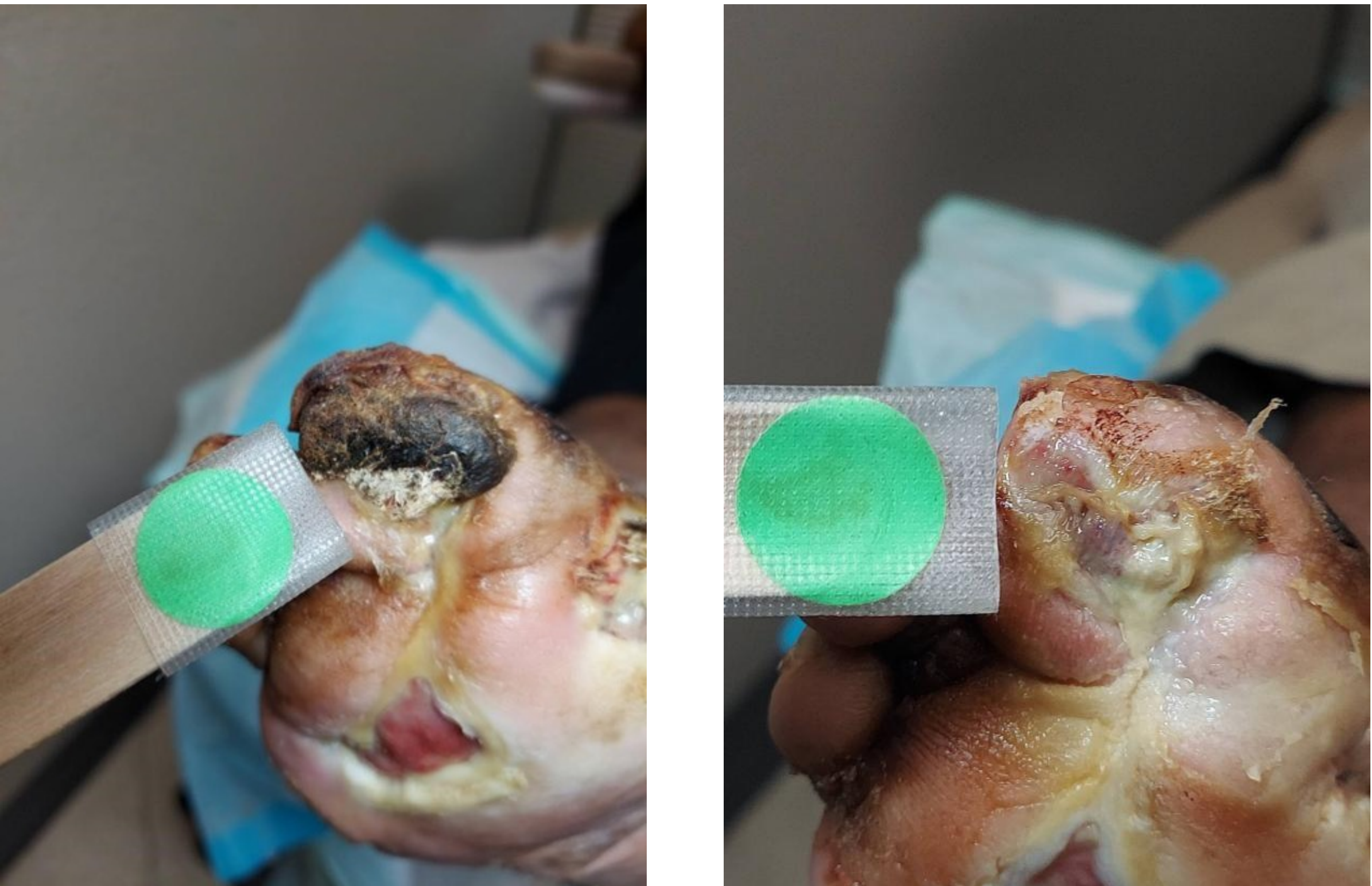
87 y/o male with Type 2 diabetes and a history of amputations. Patient's long-standing ulcer failed standard of care at multiple facilities and came to our practice with the expectation of amputation.

Two debritom⁺ procedures resulted in immediate gangrene resolution within 14 days and a graft placed.

This was a case of true limb salvage!

Patient now reports an improved quality of life.

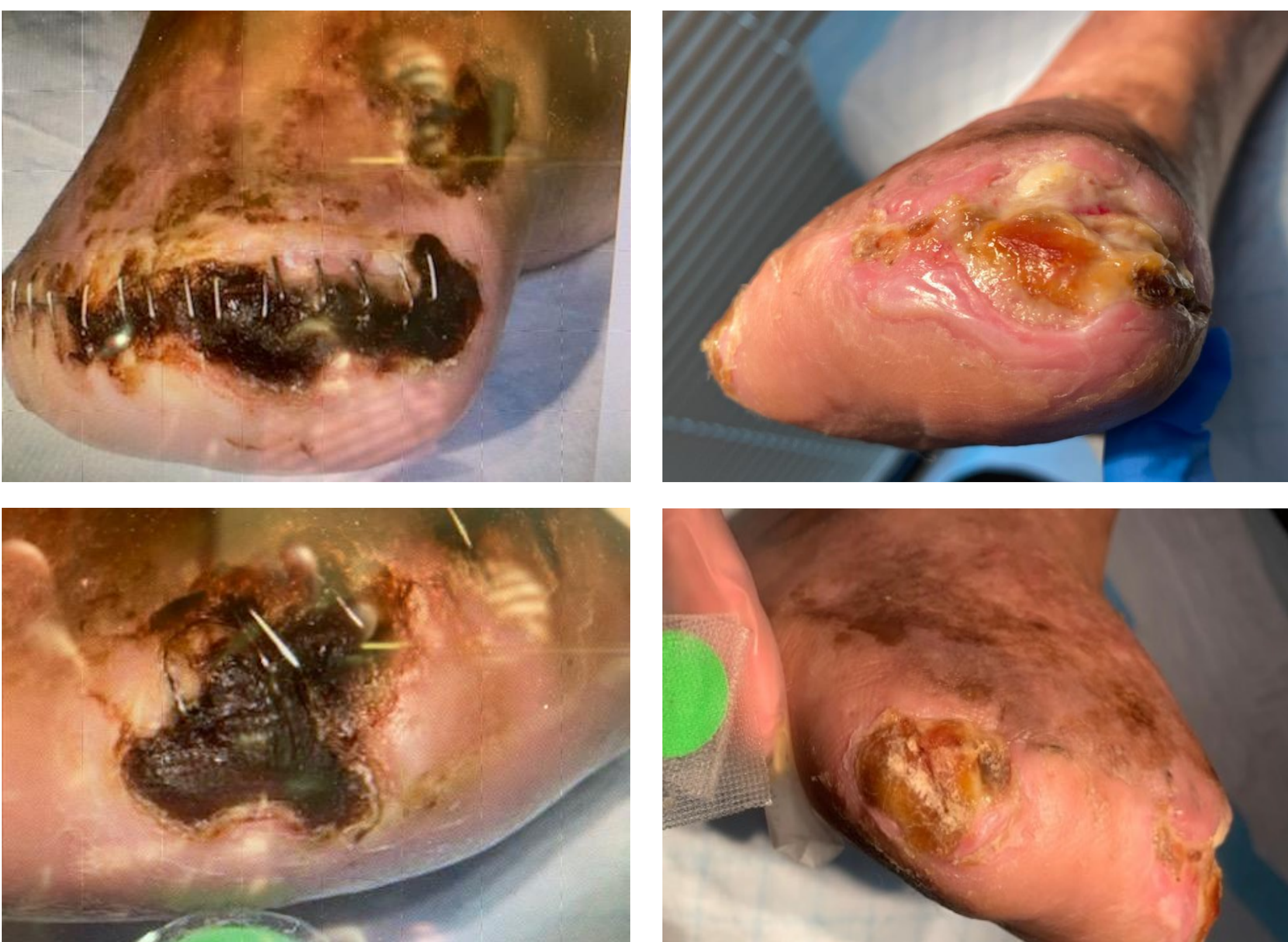Patient 2



67 y/o male with Type 2 diabetes plus amputations on the 4th and 5th digits of right foot. Patient presented with gangrenous right hallux plantar ulcer, with surgical amputation offered as an option.

Six weekly debritom⁺ procedures resulted in 17% per week reduction in wound size. With gangrene eliminated, wound healing was expedited.

Patient 3



Lower pictures are close-ups of a small section of the wound

76 y/o male with Type 2 diabetes, recent right transmetatarsal amputation, and gangrene on lateral 5th metatarsal head was offered right leg amputation.

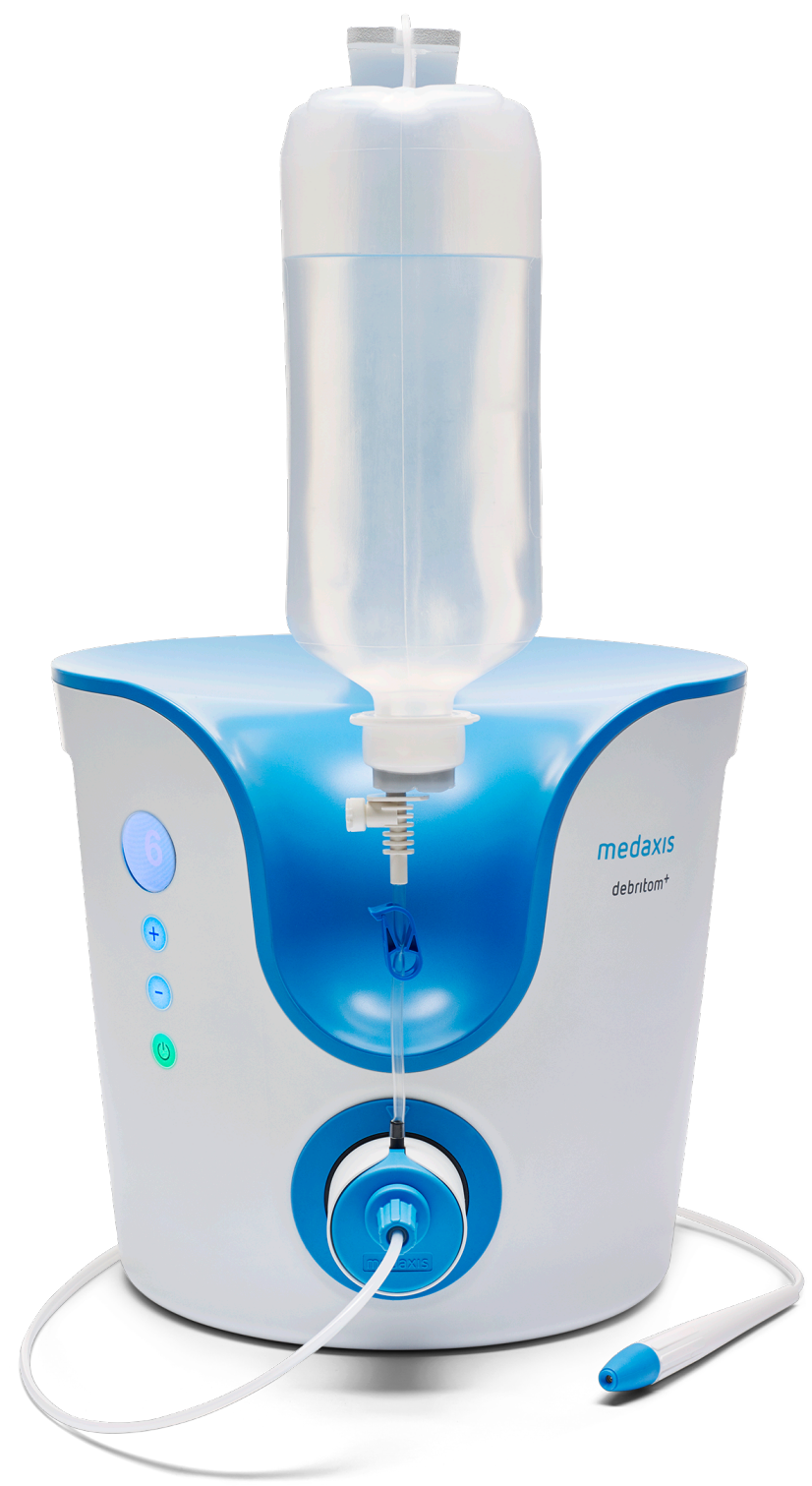Four debridements with debritom⁺ resulted in gangrene resolution and a fast graft uptake. Wound was healed in 4 weeks.

Patient reported that post-debridement his pain was reduced from severe to mild.

Conclusion

The novel micro water jet technology debritom⁺ spared patients with gangrene from amputation(s) with successful, rapid overall healing.

This technology shows great promise in limb salvage applications, improving the patient's quality of life and providing significant savings to both the patient and the healthcare system.



The debritom⁺ micro water jet debridement technology by medaxis www.medaxis.us